

# Femoral Nerve Anesthesia in Hostile Environments (Mountains)

Philippe Mahiou<sup>1,2</sup>

<sup>1</sup>Department of Anesthesiology and Intensive Care, Cedres Clinic, Echirolles, France

<sup>2</sup>Department of Emergency Medicine and French Mountain Rescue Association (ANMSM), Grenoble University Hospital, Grenoble, France

## Email address:

mahiou.phil@gmail.com

## To cite this article:

Philippe Mahiou. Femoral Nerve Anesthesia in Hostile Environments (Mountains). *International Journal of Biomedical Science and Engineering*. Vol. 10, No. 2, 2022, pp. 50-53. doi: 10.11648/j.ijbse.20221002.13

Received: May 20, 2022; Accepted: June 6, 2022; Published: June 16, 2022

**Abstract:** Traumatic injuries associated with adventure sports activities occur in hostile environment. The Femoral nerve anesthesia (FNA) outside of the hospital settings has been demonstrated but not in hostile environment. So, the objective of this study was to determine the feasibility of FNA for these very painful traumatized patients on the accident site and during their extraction-evacuation by helicopter. This prospective observational study was enrolled a convenience sample of 11 patients (4 women, 7 men) with closed fractures femurs. FNA was performed on all participants and 3 situations were defined (Impossible, Difficult if more than 1 attempt, Easy to perform). Pain evaluated using visual analog scale (VAS) (0-10) measured at the following time point: Rescue team arrival (T0), Ten minutes after FNA (T10), at Reduction of fracture (T Reduction) and during helicopter Evacuation (T Evacuation). The median age of the participants was aged 40 +/- 18 years. The accidents which occurred were 7 Skiing, 2 mountaineering, 1 snowshoeing, 1 paragliding. 11 FNA performed with 5 fascia iliaca blocks, 6 femoral nerve blocks. 82% blocks were technically easy and 18% difficult. Pain evaluation showed an average VAS of 7,5 (7-8) at T0, 1,1 (0-2) at T10, 0,45 (0-1) at T Reduction, 0,36 (0-1) at T Evacuation. All the pathologies were treated with reduction and immobilization. Helicopter evacuations were conducted without incident in a calm atmosphere and with excellent patient cooperation. In final, FNA performed in difficult environment is feasible, effective, and reproducible in extreme conditions. There is no limitation due to hostile terrain. FNA techniques used must simple and fast but performed by trained physicians who are technical experts in order achieve a successful outcome in difficult terrain.

**Keywords:** Traumatology, Hostile Environments, Prehospital Analgesia, Regional Anesthesia, Femoral Nerve Anesthesia, Helicopter Evacuation

## 1. Introduction

For more than 10 years the popularity of mountain adventure sports has continued to expand. The femoral traumatic injuries associated with these activities occur more and more in hostile environments requiring technical extraction of patients in intolerable pain [1].

The effectiveness of femoral nerve block outside of the hospital setting has been demonstrated [2]. Nevertheless, we asked ourselves if at the time of helicopter transport in a hostile environment (canyon, via ferrata, cave, high altitude) it is possible to perform this regional anesthesia on site for patients experiencing extreme pain and stress. The primary goal is to obtain a level of anesthesia sufficient to allow

reduction and immobilization of fractures or dislocations in these patients. Transport by stretcher from the treatment site (hostile environment) to the helicopter evacuation area (with or without winch) would then become a comfortable experience for the patient. Transfer to the hospital would likewise be accomplished in patient comfort with a significant decrease or absence of post-traumatic stress.

## 2. Materials and Methods

The study that we completed is a prospective observational study which took place during the winter (period from January to April). Injured patients who benefited from a femoral nerve block at the accident site were included. Information obtained included demographic data (sex and age), circumstances of the

accident and the types of injuries sustained. Additionally, the need for systemic analgesia prior to performing the regional anesthetic was noted. If a sedation was performed it was minimal and accomplished using IV medication. The sedatives used were by choice easily reversible, providing a margin of safety. Of the sedative agents which induce anxiolysis and amnesia we chose midazolam (Hypnovel®), which among the benzodiazepines is the best suited to the emergency context. Ketamine (Ketalar®) (20-30 mg IV) or sufentanil (10-15 mcg) were used if necessary to provide enough analgesia to position the patient correctly to facilitate administration of the regional block. A target Ramsey score of less than or equal to two (cooperative, oriented and tranquil) was chosen for safety given the hostile environment. In order, to prevent injury from environmental factors, the intervention site was secured by one or two first responders who were part of the medical helicopter team. In fact, participating physicians were accompanied by professional mountaineers and/or spelunkers who in addition to their qualifications as first responders are accustomed to directing high risk situations. The type of regional anesthesia was determined on site. (The use or not of neurostimulation and/or ultrasound as well as the ease of administration of regional block was noted). During administration of a regional block three situations were defined as follows: impossible to perform, difficult to perform (more than one attempt), easy to perform (one attempt). Contraindications to regional anesthesia were respected: categorical refusal by the patient or inability to consent, allergy to local anesthetics, uncorrected coagulopathy, long-term anticoagulation, progressive neurologic deficit, uncontrolled hypertension, unstable angina, decompensated heart failure and local infection at puncture site.

Two local anesthetics were used, either Mepivacaine 1% (Carbocaine®) or Ropivacaine 0.2% (Naropeine®), respecting the recommended doses delineated by the Clinical Practice Recommendations (RPC) from the European and American Society of Regional Anesthesia (ESRA and ASRA). The choice of local anesthetic by the physician would depend on the pain intensity, the rapidity of therapeutic onset, the total anticipated time of transport and the need for prolonged analgesia.

Pain was evaluated using the visual analog scale (VAS, 0 to 10) measured at the following timepoints: the arrival of the rescue team (T0), at 10 minutes after completion of the regional block (T10), during reduction of the fracture or dislocation (T Reduction), and finally during transport and evacuation of the injured (T Evacuation).

Incidents which occurred during evacuation (stretcher, helicopter), during hospitalization and any complications of regional anesthesia (local anesthetic toxicity, paresthesia, or vascular injury) were noted if they occurred.

### 3. Results

Eleven patients were enrolled: 4 women and 7 men aged 40 +/- 18 years (mean +/- SD). The pathologies encountered included 11 closed femur fractures.

All femoral nerve blocks were performed on patients

having a Glasgow Coma Score of 15 and without obvious head wounds or clinical signs of posturing.

The accidents which occurred were: 7 skiing (64%), 2 mountaineering (18%), 1 snowshoeing (9%) and 1 paragliding (9%).

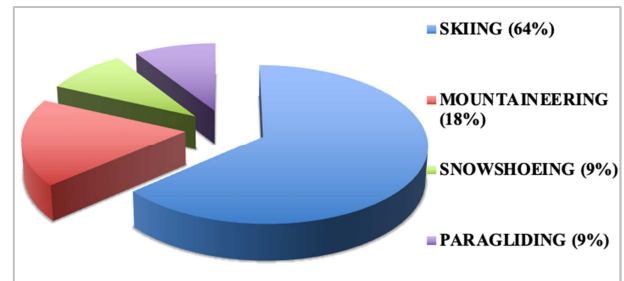


Figure 1. Etiologies of the accidents.

Four emergency medicine physicians and 3 anesthesiologists experienced in regional techniques performed 11 regional blocks in a hostile environment. These consisted of 5 fascia iliaca blocks (FICB), 6 femoral nerve blocks (FNB).

100% of the FICB were performed without neurostimulator or ultrasound using the loss of resistance technique from the two fascias lata and iliaqua [6, 7]. The 6 FNB were performed using ultrasound exclusively without neurostimulator. All regional blocks administered on site were effective, there were no failed blocks.

No paresthesia, paralysis, or sign of local anesthetic toxicity (intravascular injection, absorption) across the different procedures was reported.

Anxiolysis prior to regional anesthetic was administered to 5 patients using midazolam 2 mg IV push. Two others were additionally given 30 mg of ketamine IV, and another was given 15 mcg of sufentanil IV but without ketamine. In total 8 of 11 patients received minimal sedation prior to regional anesthesia.

The doses of local anesthetic used were 20ml (200mg) of Carbocaine® or 20ml (70mg) of Naropeine®. In total 5 patients received Carbocaine® and 6 patients received Naropeine®.

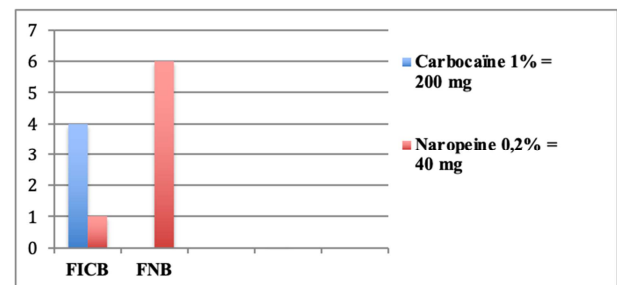
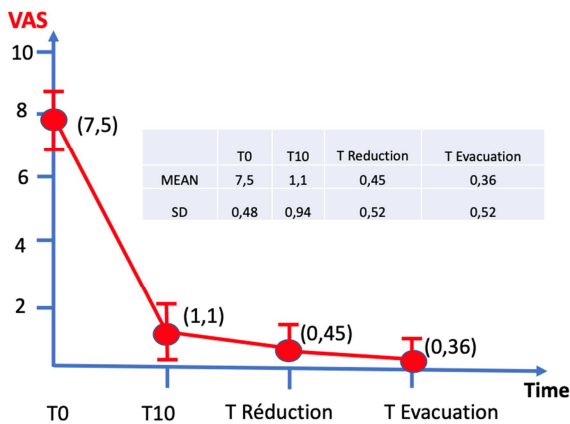


Figure 2. Breakdown of blocks and regional techniques.

In our series there were no failed regional blocks. Nine blocks (89%) were technically straightforward and 2 (11%) were difficult because the snow reverberation of light.

Evaluation of pain levels showed an average VAS score of

7,5 (7-8) before regional block (T0), 1,1 (0-2) ten minutes post block administration (T10), 0,45 (0-1) at the time of reduction (T Reduction) and 0,36 (0-1) at the time of transport and evacuation (T Evacuation).



**Figure 3.** Pain scores at T0, T10 post femoral nerve anesthesia, T Reduction, T Evacuation.

In total 11 fractures were effectively treated with reduction and immobilization. Helicopter evacuations were conducted without incident in a calm and confident manner with excellent patient cooperation. 5 winchs assisted helicopter evacuations were performed (via horizontal “Franco Garda” style litter). No complications from regional anesthesia were observed over the course of the different procedures.

## 4. Discussion

The indications for femoral nerve anesthesia in the emergency setting are all femur fractures. The use of femoral nerve blocks allows one to avoid, in hostile terrain, the major risks of general anesthesia with rapid sequence induction in a non-fasting patient [16]. Whether or not the patient recently had a meal, trauma will induce an ileus. The severity of pain will often lead to a general anesthetic, and therefore a rapid sequence induction with the risks of aspiration, orotracheal intubation or anaphylactic reaction to succinylcholine. These trauma patients are mobilized and transported to the helicopter evacuation site to be loaded into the helicopter (by various means). The use of a strong and reproducible analgesic is therefore necessary. By reducing the use of morphine, regional anesthesia allows reduction or elimination of morphine side effects (nausea, vomiting, pruritis, etc.). Femoral nerve block is superior in terms of analgesia while resting and during mobilization as compared to morphine and other opioids [3]. Now among regional techniques the femoral nerve block has become the standard for pre-hospital pain management for fractures of the femoral shaft [4, 5] and femoral neck fractures [6, 14, 15]. These femoral nerve blocks that were administered in the field under dangerous conditions were effective, reproducible and of high quality. The mobilization and transport of these trauma victims in a difficult environment should proceed more smoothly and securely as compared to patients under

general anesthesia with or without intubation. Among the other advantages of regional anesthesia, it can provide a reduction in post-traumatic stress, prevent the development of chronic pain through a strong analgesic effect and facilitate patient rehabilitation due to rapid onset analgesia for pain control both at rest as well as during mobilization.

Our study demonstrates that femoral nerve block performed in a difficult environment is feasible, effective, and reproducible even in extreme conditions. There is no limitation due to hostile terrain. However, one must bear in mind that this type of regional anesthesia must be simple and rapid to execute. There is no question that during this type of intervention, in a difficult to reach location, one should not stay longer than necessary. These regional blocks, performed with little or no sedation, are well tolerated by the trauma victims and provide very strong analgesic effects. Femoral nerve block enables pain free reduction and immobilization of fractures or dislocations while maintaining the ability to monitor neurologic status. This is critical in patients who have suffered a head trauma and need to be frequently assessed for clinical signs (Glasgow Coma Scale, posturing) of an intracranial process (epidural or subdural hematoma) without being masked by deep sedation or general anesthesia [17]. Another important point to consider is the positive psychological effect on the patient and rescue team who can confidently complete the evacuation in a calm atmosphere, sometimes with active participation of the injured thus avoiding the hazards associated with stretcher transportation.

With respect to technique, it should be possible to complete all the femoral nerve blocks using ultrasound guidance. Certainly, a FICB could be performed without neurostimulation or echocardiography [9, 10]. The major advantage is that it can be done quickly in case it is necessary to affect a rapid extraction for reasons related to weather or risks associated with the terrain (rockslides, avalanche, etc.). It is important to note that the regional block must be analgesic but not necessarily anesthetic in nature. Nevertheless, ultrasound guidance allows regional blocks to be performed more easily and reliably [7] which is important for all concerned (patient, medical team, helicopter evacuation team) in this high-stakes situation.

The drawbacks to femoral nerve anesthesia include the complexity of the procedure, length of training and the number of procedures needed to be performed on a regular basis to maintain competence with various techniques. This technical regional nerve block is invasive procedures which carry risks of infection, nerve damage [11, 12] and local anesthetic toxicity [8]. Despite the advantages of this femoral nerve anesthesia its use is often shunned by certain physicians due to potential risks. Most often this is due to lack of adequate training or understanding of techniques [13]. Unfortunately, only a small number of medical providers intervening in dangerous environments possess the education and experience to safely perform regional anesthesia. Lack of provider expertise in the field could lead to dangerous delays and slow down evacuation of the wounded. Increased training and benchmarks for number of blocks performed

could help to overcome this problem and allow a better targeted analgesic intervention for trauma victims.

The choice of local anesthetics should also be well thought out. One must consider the complexity of the procedure to be performed at the accident site as well as the analgesic time needed to complete reduction of fracture or dislocation, evacuation, and arrival at the hospital. The weak local anesthetics which exhibit a short onset (5-10 minutes depending on the site) and a duration of action of 1.5-2 hours include lidocaine, prilocaine and mepivacaine. The stronger local anesthetics, having a longer onset time (10-20 minutes) and a duration of action of 2.5-3.5 hours are ropivacaine and L-bupivacaine. In our study the choices came down to mepivacaine 1% (Carbocaine®) or ropivacaine 0.2% (Naropaine®) because of their low risk of toxicity in case of inadvertent intravascular injection or absorption [11]. Dose maximums were adhered to and are referenced on the RPC from ESRA and ASRA.

## 5. Conclusions

It is possible to perform femoral nerve block on site even under adverse conditions. The femoral nerve anesthetic techniques (FICB or FNB) used must be simple and fast but performed by trained physicians who are technical experts in order to achieve a successful outcome in difficult terrain. As discussed in this article there are numerous advantages to highlight. The use of regional femoral nerve-anesthesia is safer than general anesthesia or deep sedation with respect to risk of complications. Therefore, the risk/benefit assessment favors this choice. This technical regional anesthesia allows treatment of acute pain as well as reduction and immobilization of acute fractures or dislocations. These femoral nerve anesthetic techniques are already recommended for use in the pre-hospital arena by the Société Française de Médecine d'Urgence (SFMU): FICB without neurostimulation or ultrasound guidance and FICB with or without neurostimulation using ultrasound guidance for analgesic treatment of femur fractures. It would also be possible to follow this recommendation in hostile environments.

In the future this regional anesthesia will be taught by a mentor through apprenticeship in the operating room using ultrasound guided techniques (reduced risk of local anesthetic toxicity). The risk/benefit tradeoff must always be evaluated in the hostile environment. One must not forget to have Intralipid 20% accessible in the regional anesthesia kit in case of the need to immediately treat local anesthetic toxicity, which is always a possibility at the treatment site.

## References

- [1] Ellerton J., Milani M., MD, Blancher M., Zen-Ruffinen G., Christjar Skaiaa S., Brink B., Lohani A., Paal P. Managing Moderate and Severe Pain in Mountain Rescue- High Altitude Medicine & Biology 2014;15 (1): 8-14. doi. 10.1089/ham.2013.1135.
- [2] Recommandations formalisées d'experts - Anesthésie locorégionale périnerveuse (ALR-PN). (Expert panel guidelines on perineural anesthesia) - Société Française d'Anesthésie et de Réanimation (SFAR) 2016.
- [3] Kettner SC, Willschke H, Marhofer P. Does regional anaesthesia really improve outcome? Br J Anaesthesia 2011; 107 (Suppl 1): i90-i95.
- [4] Beaudoin FL, Nagdev A, Merchant RC, Becker BM. Ultrasound-guided femoral nerve blocks in elderly patients with hip fractures. Am J Emerg Med 2010; 28: 76-81.
- [5] Pennington N, Gadd RJ, Green N, Loughenbury PR. A national survey of acute hospitals in England on their current practice in the use of femoral nerve blocks when splinting femoral fractures. Injury 2012; 43: 843-845.
- [6] Elkhodair S, Mortazavi J, Chester A, Pereira M. Single fascia iliaca compartment block for pain relief in patients with fractured neck of femur in the emergency department: a pilot study. Eur J Emerg Med 2011; 18: 340-343.
- [7] Dolan J, Williams A, Murney E, et al. Ultrasound guided fascia iliaca block: a comparison with the loss of resistance technique. Reg Anesth Pain Med 2008; 33: 526-53.
- [8] Drasner K. Local anesthetic systemic toxicity. Reg Anesth Pain Med 2010; 35: 162-166.
- [9] Lopez S, Gros T, Bernard N, Plasse C, Capdevilla X. Fascia iliaca compartment block for femoral bone fractures in préhospital care. Reg Anesth Pain Med 2003; 28: 203-207.
- [10] Fortin JL, Astraud C, Fuilla C, Lallement D, Dubourdieu S, Ruttimann M, Zimmermann MP, Kowalski JJ. Epidémiologie et pratique du bloc iliofascial en situation extra-hospitalière à la Brigade des Sapeurs-Pompiers de Paris. Urgence Pratique 2005; 73: 29-31.
- [11] Delaunay L. Complications des blocs tronculaires et plexiques. Le Praticien en Anesthésie-Réanimation 2001; 5: 267-275.
- [12] Auroy Y, Benhamou D, Bargues L, Ecoffey C, Falissard B, Mercier F, Bouaziz H, Samii K. Major complications of regional anesthesia in France: the SOS regional anesthesia hotline service. Anesthesiology 2002; 97: 1274-1280.
- [13] Ageron FX, Metton P, Casimiri ML, Binault G, Savary D, Belle L, Perfis JP. Enquête sur les pratiques d'anesthésie locorégionale par les urgentistes au sein d'un réseau interhospitalier. JEUR 2007; 20: S25-S28, 54.
- [14] Foss N. B., Kristensen B. B., Bundgaard M. and al. Fascia iliaca compartment blockade for acute pain control in hip fracture patients: a randomized, placebo-controlled trial. Anesthesiology 2007, vol. 106, n°4: 773-778.
- [15] Beaudoin F. L., Nagdev A., Merchant R. C., and Becker B. M. Ultrasound-guided femoral nerve blocks in elderly patients with hip fractures. American Journal of Emergency Medicine 2010, vol. 28, n°1, 76-81.
- [16] American College of Emergency Physicians: Rapid-sequence intubation. Ann Emerg Med April 1997; 29: 573.
- [17] Fuzier R., Richez A. S., Olivier M. Regional anesthesia techniques in emergency setting. Reanimation 2007; 16: 660-664.